

## CASE REPORTS

# Pre and Postoperative Evaluation of Cutaneous Facial Flaps Using Infrared Thermographic Camera

Laura Raducu<sup>1,2</sup>, Cristina Nicoleta Cozma<sup>2</sup>, Laura Oana Stroica<sup>3</sup>, Tiberiu Paul Neagu<sup>2</sup>, Cristian Radu Jecan<sup>1,2</sup>

## Abstract

**Introduction:** Skin flaps are often used for reconstructing cutaneous defects. Based on their blood supply these are classified in random and axial flaps, the success of their survival being adequate perfusion. Infrared thermographic camera measures the skin temperature, influenced by vessel distribution. **The objectives of the study:** The purpose of this paper is to evaluate the skin vascularization using the thermographic camera in order to design viable facial flaps. **Used methodology:** We present the cases of three patients with facial defects reconstructed using local and regional flaps whose vascularization was monitored pre and postoperatively using a thermal camera. No local complications occurred and aesthetic and functional outcome was good. **Conclusions:** Infrared thermographic camera might represent a new method of evaluating flap vascularization that could help in minimizing ischemic complications in flap surgery.

**Keywords:** facial reconstruction, axial flap, infrared thermographic camera

## Rezumat

**Introducere:** Lambourile tegumentare sunt frecvent folosite în acoperirea defectelor cutanate. În funcție de vascularizație, lambourile sunt clasificate în lambouri cu circulație întâmplătoare sau cu circulație axială, supraviețuirea acestora fiind condiționată de perfuzia adecvată. Camera cu termoviziune în infraroșu măsoară temperatura pielii ce este influențată de distribuția vasculară. **Obiective:** Scopul acestei lucrări a fost de evaluare a vascularizației pielii cu ajutorul camerei cu termoviziune pentru a realiza lambouri cutanate faciale viabile. **Metodologie:** Sunt prezentate cazurile a trei pacienți cu defecte faciale acoperite prin lambouri locale și regionale, a căror vascularizație a fost monitorizată pre și postoperator folosind camera prin termoviziune. Postoperator nu au existat complicații, iar rezultatele funcționale și estetice au fost acceptabile. **Concluzii:** Camera cu termoviziune în infraroșu poate constitui o nouă modalitate de evaluare a vascularizației lambourilor, minimizând astfel apariția complicațiilor ischemice în chirurgia lambourilor.

**Cuvinte cheie:** reconstrucție facială, lambou axial, cameră cu termoviziune în infraroșu

<sup>1</sup> „Carol Davila”, University of Medicine and Pharmacy, Bucharest, Romania

<sup>2</sup> Department of Plastic and Reconstructive Surgery, „Prof. Dr. Agrippa Ionescu” Clinical Emergency Hospital, Bucharest, Romania

<sup>3</sup> Department of Anatomy, „Carol Davila” University of Medicine and Pharmacy, Bucharest, Romania

### Corresponding author:

**Laura Raducu**

Department of Plastic and Reconstructive Surgery, „Prof. Dr. Agrippa Ionescu” Clinical Emergency Hospital, Bucharest, Romania.

E-mail: raducu.laura@yahoo.com

## INTRODUCTION

Cutaneous flaps are usually utilized in covering skin defects in different parts of the body. Facial reconstruction is an important topic for plastic and reconstructive surgeons, facial defects having a serious impact on patient's quality of life<sup>1</sup>.

The most critical factor in designing a local flap is the knowledge of its source of vascularization. Based on their blood supply, local flaps can be classified in random flaps and axial flaps. Random flaps depend on the vascularization from the subdermal plexus and the survival is influenced by the perfusion pressure, not on the tradition concept of width to length ratio<sup>2</sup>. Axial flaps have a specific blood vessel which confers a predictable blood supply and improves survival lengths. This flap can be completely removed from the surrounding tissue as long as it has its pedicle. The main difficulty in creating this flap is locating the blood vessels and protecting them<sup>3</sup>. Axial flaps used in face reconstruction can be local flaps as paramedian forehead flap, regional flaps as deltopectoral flap and free flaps such as radial forearm flap. Free flaps are the most difficult axial flaps, having the blood supply dependent on the revascularization of an individual anastomosed artery<sup>2</sup>.

Local and regional axial flaps are usually designed considering description of the anatomical landmarks, but in some cases anatomical variations may interfere and cause difficulties in discovering the pedicle<sup>4</sup>.

Thermal imaging has a broad spectrum of application in plastic surgery, including assessment of burn depth and detection of cutaneous vessels. The thermal camera detects infrared radiation realizing an image based on local temperature which is influenced by cutaneous blood flow<sup>5</sup>.

In order to improve the technique and to minimize complications after realizing an axial flap we evaluate the facial cutaneous vascularization of three patients and the location of the flap pedicle using an infrared thermal camera.

## MATERIAL AND METHODS

### Case 1

We describe the case of an 87 year old male patient with hypertension and cardiomyopathy admitted in our department with a ulcerated, bleeding tumoral mass involving the lower lip, the left labial commissure and the left quarter of the upper lip.

Considering the additional comorbidities, the patient's age and the size of the tumor, a regional axial flap as deltopectoral flap was chosen to realize the re-

construction of the defect. Preoperative thermographic pictures were realized to discover the vascularization and to design the flap. The deltopectoral flap is a fasciocutaneous regional flap with a vascular supply from the first through fourth perforating branches of the internal thoracic artery. The flap was designed larger than the size of the defect, and it was raised including the fascial layers of pectoralis major and deltoid muscles which transmit the perforating vessels. The flap was elevated 2 cm lateral the sternum to not injure the perforators and was rotated to close the defect of the lower lip and left commissure. The donor defect was sutured as possible and the rest was split-skin grafted.

The flap was evaluated postoperatively using the thermal infrared camera showing a good vascularization from the perforators (Figure 1,2). No complications occurred and the histopathological exam revealed a squamous cell carcinoma with free resection margins. Flap vascularization improved from week to week and after four weeks the skin bridge was divided, the flap having its own new vascularization. The type of reconstruction chosen was determined in this case by the patient's comorbidities and the defect size, the goals of the lip reconstruction included the restoration of oral competence, mobility, and maintenance of oral aperture which permit the re-entry of the patient back into society<sup>6</sup>.

### Case 2

A 68 year old male patient was hospitalized in our department with a recurrent basal cell carcinoma of the medial canthus of the left eye. In the last ten years he had previous five surgeries and radiotherapy treatment.

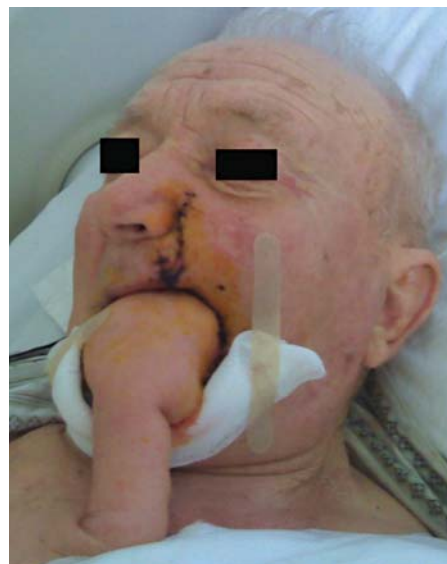

Figure 1. Day 2 after surgery result.




**Figure 2.** Good vascularization from the perforators (day 2 after surgery).

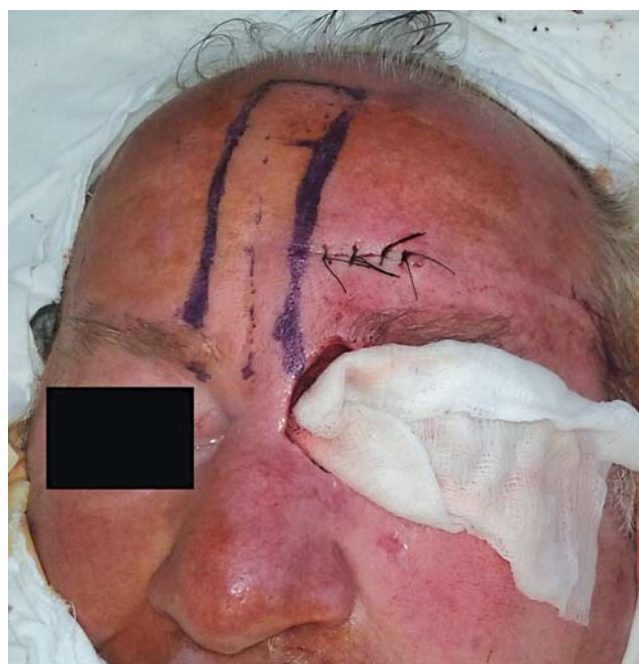We decided to excise the tumoral mass and to reconstruct the defect using a paramedian forehead flap. The flap was evaluated using the infrared thermal camera which allowed us to detect the supratrochlear artery (Figure 3) and to design the narrow pedicle of the flap (Figure 4). We excised the tumoral mass with a 0.5 cm margins and we covered the defect of the medial canthus using a paramedian forehead flap from the opposite side. The flap was harvest superficial to the frontalis muscle in the distal part and next to the periosteum in the proximal part. The flap showed a good vascularization on the postoperatively evaluation with the termographic camera and no complication occurred.

### Case 3

We describe the case of a 62 year old male patient who was admitted in our department with a bleeding and

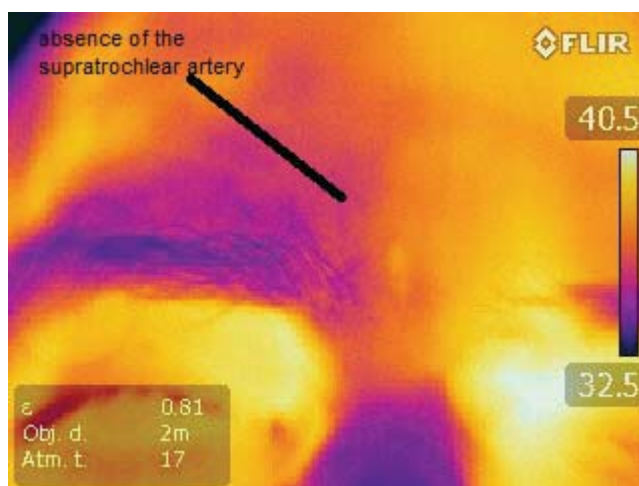


**Figure 3.** Supratrochlear artery seen on infrared thermal camera.



**Figure 4.** The design of the paramedian forehead flap pedicle.

ulcerated tumoral mass involving the medial canthus of the left eye and the glabella. Reconstruction using an opposite paramedian forehead flap was considered and evaluation of the local vascularization was performed using the thermal infrared camera. Despite expectations, the thermal camera showed no flow in the opposite supratrochlear artery that would determine a poor vascularization of the paramedian forehead flap with a higher rate of necrosis (Figure 5). So, we decided to reconstruct the defect using local advancement flaps from the cheek and forehead. Postoperative evaluation showed a good vascularization of the reconstructed area with no further complications.



**Figure 5.** No flow in the right supratrochlear artery.

Patient's images were recorded with the thermographic camera Flir E50 at a resolution of 240×180 pixels, frequency of 60 Hz and a thermal sensitivity of 0.05°C. The pictures were realized in a room with a constant temperature of 24°C, 60% humidity, after a period of 5 minutes used for accommodating to the room temperature and environmental conditions. The images were realized with the camera perpendicular to the face and at a distance of 30 cm from the skin's surface. Pictures were processed using a Flir Systems Software

## DISCUSSIONS

Facial reconstruction is one of the most demanding parts of reconstructive plastic surgery, relying on the surgeon's creativity and on understanding the properties of local flaps. Choosing the correct method of reconstruction starts with the analysis of the defect and of the patient's history and evaluation of the local options<sup>4</sup>. Loco-regional flaps provide an excellent color match and are generally fail-safe. In order to ensure viability, the design of every flap has to respect its vascular supply<sup>7</sup>. This is the main condition for flap survival and for minimizing complications.

Infrared thermography is an auxiliary diagnostic imaging device that detects infrared radiation from an object, measuring the temperature. Considering that skin temperature is influenced by vascularization, thermal imaging can be used as a reflection of the cutaneous blood flow<sup>8</sup>.

One of its main advantages could be considered the absence of radiation or intravenous contrast agents and also the fact that is fast and easy to use.

We have successfully used thermal infrared camera as a novel method for monitoring pre and postopera-

tive flaps used for reconstructing facial defects. This technique besides monitoring local temperature permits the discovery of patent vessels that can be used to design different flaps. Also, thermal camera was used postoperatively for monitoring the flaps, especially in choosing the right moment for cutting the pedicle of a delayed deltopectoral flap. No local complications encountered and functional and esthetic results were satisfactory.

## CONCLUSIONS

Reconstruction of facial defects represents a very important part of plastic surgery, having a wide range of surgical options. The successful recovery of the patient and its social reintegration depend of the functional and aesthetic result. Considering the good match of color, structural characteristics and texture, local and regional flaps are considered the best solution for facial defects reconstruction.

Infrared thermography could represent a new and non-invasive investigation method of the subcutaneous vascularization, having the premises to be used as a pre and postoperative method of flap evaluation for minimizing ischemic complications in surgery flap.

**Acknowledgment:** This paper was part of the "Research project on the establishment, management and functioning of a surgery excellence center in cutaneous malign tumors" co-financed through the research grant number 128/01.08.2016, offered by S.C. Medical Prestige S.R.L., coordinator University of Medicine and Pharmacy "Carol Davila", Bucharest, Romania.

## References

1. Pepper JP, Baker SR. Local flaps: cheek and lip reconstruction. *JAMA Facial Plast Surg.* 2013 Sep-Oct;15(5):374-82.
2. Patel, Krishna G. et al Concepts in local flap design and classification. *Operative Techniques in Otolaryngology-Head and Neck Surgery*, Volume 22, Issue 1, 13-23.
3. Nadine B Semer, Local flaps. In Nadine B Semer, *Practical Plastic Surgery for Nonsurgeons*, pg 111-120. 2007.
4. Hallock GG, Morris SF. Skin grafts and local flaps. *Plast Reconstr Surg.* 2011 Jan;127(1):5e-22e.
5. de Weerd L, Mercer JB, Setså LB. Intraoperative dynamic infrared thermography and free-flap surgery. *Ann Plast Surg.* 2006 Sep;57(3):279-84.
6. Nthumba P, Carter L. Visor flap for total upper and lower lip reconstruction: a case report. *Journal of Medical Case Reports.* 2009;3:7312.
7. Maciel-Miranda A, Morris SF, Hallock GG. Local flaps, including pedicled perforator flaps: anatomy, technique, and applications. *Plast Reconstr Surg.* 2013 Jun;131(6):896e-911e.
8. Hardwicke JT, Osmani O, Skillman JM. Detection of Perforators Using Smartphone Thermal Imaging. *Plast Reconstr Surg.* 2016 Jan;137(1):39-41.